Effectiveness of combined arthrocentesis with platelet-rich plasma, platelet rich-fibrin, hyaluronic acid, corticosteroids and non-steroidal anti-inflammatory drugs in temporomandibular joint osteoarthritis: a systematic review and meta-analysis of randomized clinical trials

Marilia Betancor Pérez, PhD,[a,b] Juan Francisco Loro Ferrer, PhD,[d] Fátima Martín Hernán, PhD,[e] and Rocío Trinidad Velázquez Cayón, PhD[b,c]

Objective. To stablish whether combined arthrocentesis with platelet-rich plasma, fibrin-rich plasma, hyaluronic acid, corticosteroids and non-steroidal anti-inflammatory drugs is more effective than exclusive arthrocentesis in patients with temporomandibular joint osteoarthritis.

Study Design. A bibliographic search was conducted in Pubmed, Web of Science, Embase and Scopus in July 2024. RCTs were included. The PRISMA checklist was followed. The study is registered with PROSPERO, number CRD42024542631.

Results. Six RCTs were included with a total of 179 patients. For the variable of maximum oral opening, a better response was observed in the combined arthrocentesis group than in the arthrocentesis group at 6 months ($P = .011$) and at 12 months ($P < .001$). For the pain variable, there were no significant differences between the groups at 6 months ($P = .300$) while at 12 months a better response was observed for the experimental group ($P < .001$).

Conclusion. Combined arthrocentesis techniques show significant improvements in maximum mouth opening at six and twelve months and in pain at twelve months pos-treatment. However, the lack of protocol development and the scarcity of similar studies highlight the heterogeneity of the results. (Oral Surg Oral Med Oral Pathol Oral Radiol 2025;140:528−538)

Temporomandibular disorders (TMD), present a multifactorial etiology and varied, complex clinical manifestations that represent a significant group of chronic orofacial pain.[1-4] Within the classifications of TMD, those associated with aging and traumatic processes are known as temporomandibular joint (TMJ) degenerative diseases.[5] Among these, the one that presents with inflammation and pain, in addition to other functional limitations, is known as osteoarthritis, a highly prevalent disease in the adult population.[6-8]

The Research Diagnostic Criteria for Temporomandibular Joint Diseases (RDC/TMD classification, 1992)[9] and the Diagnostic Criteria for Temporomandibular Joint Diseases (DC/TMD classification, 2014),[10] serve as standardized frameworks for the diagnosis and classification of TMD. These classifications provide a structured approach for identifying the clinical manifestations and pathological features of TMD. The RDC/TMD focuses on initial diagnostic protocols, classifying TMD into three main groups: group I (muscular disorders or myofascial pain), group II (disc displacements), and group III (arthralgia, osteoarthritis and osteoarthrosis).[11] Meanwhile, the DC/TMD incorporates updated clinical insights and refined diagnostic parameters to improve diagnostic accuracy and reliability, introducing two diagnostic parameters: Axis I (physical aspects) and Axis II (psychosocial aspects).

When treatment with conservative therapies alone is not effective, other minimally invasive surgical techniques such as arthrocentesis or arthroscopy can be employed.[12,13] In 1991, Nitzan[14] described arthrocentesis as a simple technique that, through the hydraulic pressure exerted by a lavage solution in the glenoid cavity, allows the release of inflammation mediators and adhesions that may be present.[15-17] Studies confirm

Statement of clinical relevants

In the treatment of patients with temporomandibular joint osteoarthritis, combined arthrocentesis shows better results in maximum oral opening values in the medium and long term, as well as reduces pain in the long term.

[a]Doctorate Program in Health Sciences, Faculty of Health Science, University of Las Palmas de Gran Canaria (ULPGC), Las Palmas de Gran Canaria, Spain.
[b]Department of Dentistry, Faculty of Health Science, Fernando Pessoa Canarias University (UFPC), Santa María de Guía, Spain.
[c]Centro Universitario San Isidoro, Pablo de Olavide University (UPO), Sevilla, Spain.
[d]Clinical Sciences Department, Faculty of Health Science, University of Las Palmas de Gran Canaria (ULPGC), Las Palmas de Gran Canaria, Spain.
[e]Department of Dentistry, Alfonso X El Sabio University (UAX), Madrid, Spain.
Corresponding author: Marilia Betancor Pérez E-mail address: marilia.betancor101@alu.ulpgc.es
Received for publication Apr 3, 2025; accepted for publication Jun 4, 2025.
© 2025 The Author(s). Published by Elsevier Inc. This is an open access article under the CC BY license (http://creativecommons.org/licenses/by/4.0/)
2212-4403/$-see front matter
https://doi.org/10.1016/j.oooo.2025.06.003

the validity and effectiveness of arthrocentesis, showing that approximately 70-90% of cases experience improvement in the manifestation of signs and symptoms prior to treatment.[18]

To date, with the aim of enhancing the effects of arthrocentesis, various elements have been incorporated either in combination or individually in the form of intra-articular injections: corticosteroids, nonsteroidal anti-inflammatory drugs (NSAIDs), hyaluronic acid, platelet-rich plasma (PRP) and platelet-rich fibrin (PRF).[19,20]

PRP and PRF are obtained through a density gradient centrifugation process of the patient's own blood and are rich in growth factors, although PRF has a higher concentration of leukocytes, fibrin, and growth factors that are gradually released, resulting in a more prolonged anti-inflammatory response.[21] Hyaluronic acid is a naturally produced non-sulfated glycosaminoglycan that, in osteoarthritis, exhibits a reduction in its molecular weight and concentration in synovial fluid.[22,23] External administration reactivates biochemical mechanisms that allow the regeneration of articular fibrocartilage, inhibit inflammation and induce the extracellular matrix synthesis.[24] Corticosteroids administered intra-articularly have been widely described as suppressors of the inflammatory response and used in the treatment of arthritis, including the TMJ,[25] although some authors suggest they cause irreversible joint damage.[18] NSAID are inhibitors of cyclooxygenase 1 and 2, demonstrating prolonged anti-inflammatory and analgesic effects when administered intra-articularly compared to oral or intravenous routes.[26]

Combined arthrocentesis and intra-articular injection techniques have gained popularity in recent times. However, the heterogeneity of results continues to generate controversy regarding which technique is more effective. Following this foundational principle, several systematic reviews and meta-analyses have addressed this issue for various TMD.[17,27-30] Nevertheless, considering that isolated arthrocentesis is already effective on its own[30] in the treatment of TMJ osteoarthritis,[31] it is worth questioning whether combined arthrocentesis provides significant improvements in treatment outcomes. Therefore, the objective of this systematic review and meta-analysis is, with the current evidence, to conduct a direct comparison of the effectiveness between combined arthrocentesis and arthrocentesis without complementary drugs in the treatment of TMJ osteoarthritis.

METHODS

Protocol recording

The review was conducted in accordance with the PRISMA (Preferred Reporting Items for Systematic Reviews and Meta-Analyses) guidelines,[32] and the study protocol has been registered in the PROSPERO database under identification number CRD42024542631.

Focused question

In the treatment of osteoarthritis of the temporomandibular joint, how much more effective is combined arthrocentesis compared to exclusive arthrocentesis in the medium and long term?

The PICO strategy was employed to frame the eligibility criteria. Included studies needed to address all components of PICO strategy, as detailed below:

- Participants: Patients diagnosed with TMJ osteoarthritis.
- Intervention: Arthrocentesis technique with a drug or autologous element is applied in one or several sessions.
- Comparison: Exclusive arthrocentesis technique applied using Ringer's lactate or normal saline.
- Outcomes: Maximum mouth opening and pain.

Eligibility criteria

Randomized clinical trials (RCTs) with humans with a follow-up of at least three months were included. The search was conducted without restrictions on publication times. Included studies needed to address control groups, the exclusive arthrocentesis technique is applied using Ringer's lactate or normal saline. In the experimental groups, following the same arthrocentesis technique as the control group, a drug or autologous (PRP, PRF, hyaluronic acid, NSAID, and corticosteroids) element is applied. The exclusive application of some of these substances in the experimental group is excluded from this review. The necessary inclusion criteria for the studies required that the variables studied were those related to the main clinical manifestations of TMJ osteoarthritis: maximum mouth opening (or maximun intercisal opening) in millimeters and pain measured on a Visual Analog Scale (VAS). Studies without a control group, descriptive and analytical observational studies, systematic reviews, and letters to the editor were excluded.

Information sources and search strategy

In July 2024, a comprehensive bibliographic search was carried out across databases including PubMed, Web of Science, Scopus, and Embase. The descriptors were selected from the Medical Subject Headings (MeSH) terms and combined through Boolean operators. A customized search strategy was implemented for each database. The search strategy can be accessed in Supplementary Table 1.

Study selection

Post-database searches, duplicates were eliminated using the Zotero bibliographic reference manager (version 6.0.26, Corporation for Digital Scholarship: Vienna, USA, 2024). The initial screening process involved reviewing titles and abstracts, followed by full-text reading for final selection. Inclusion and exclusion criteria were strictly adhered to throughout. Two reviewers (M.B.P., R.T.V.C.) independently evaluated the remaining articles, with a third reviewer (J.F. L.F.) involved resolving any discrepancies. The Kappa concordance test produced a coefficient of 0.75, signifying substantial agreement and strengthening the reliability of the study selection process.

Data collection

For each eligible RCT, a form was created to extract relevant information, such as trial design characteristics (blinding, follow-up time, sample size), participant characteristics (gender, age, diagnosis), and outcomes obtained in each RCT (intervention, common variables considered, follow-up times).

Risk of bias within individual studies

The individual risk of bias of the selected studies was evaluated using the Joanna Briggs Institute's questionnaire for RCTs.[33] This form consists of thirteen questions related to research methodology. Two independent reviewers completed each questionnaire. For each domain, we assign a response with a numerical value to estimate the bias risk category. Thus, each study was individually classified into three possible categories: low risk of bias, moderate risk of bias and high risk of bias. For low-quality RCTs, the authors were contacted to resolve doubts, but no response was received. In this systematic review, all RCTs that met the eligibility criteria were included. Clinical trials with high risk of bias were excluded from the meta-analysis.

Effect measures

To evaluate the efficacy of both, the main measurement variables for the signs and symptoms associated with TMJ osteoarthritis were considered: maximum mouth opening and pain. Maximum mouth opening values are obtained by measuring the distance between the incisal edges of the upper and lower central incisors with a millimeter ruler (maximun intercisal opening). Oral opening is considered limited when it is less than 35mm or 40mm. The pain variable is obtained through patient perception using a 10 cm visual analog scale, where 0 translates to "no pain" and 10 to "maximum pain." A scale from 0 to 100 was also used. All these data were obtained before starting the treatment, during the treatment, and/or at the end of the treatment.

Certainty of the evidence

To assess the certainty of the evidence, the Grading of Recommendations, Assessment, Development, and Evaluation (GRADE) was used.[34] GRADE classifies the quality of evidence into four categories (high, moderate, low, and very low). RCTs are considered high-quality by default, with the potential to increase or decrease the quality rating based on a series of factors (risk of bias, imprecision, inconsistency, indirectness, and publication bias).

Statiscal analysis

Four meta-analyses were conducted using the meta package v.5.2-0.[35] Common and random effect models were used to estimate the weighted averages of changes in maximum mouth opening and pain at six months and twelve months. The 95% confidence interval (95%-CI) for the estimates was calculated. Heterogeneity between studies was evaluated using Cochran's Q statistic and the I^2 statistic. A p value $< .05$ in Cochran's Q test would indicate the presence of significant heterogeneity. Additionally, the τ^2 statistic was calculated to quantify variability between studies. In all analyses, $\alpha = 0.05$ was used.

The mean difference was calculated in the meta-analysis, considering that the data are quantitative and weighting the studies by their sample size. Although two types of meta-analyses (fixed effects and random effects) were carried out, the interpretation of one or the other was based on the heterogeneity test, which is performed simultaneously with the meta-analysis. Subgroup and sensitivity analyses were not planned.

RESULTS

After removing duplicates, 1976 articles were obtained for screening by title and abstract. After this review, 48 articles were selected for further examination, only those meeting the eligibility criteria were included, with seven studies selected for the systematic review and six of them further analyzed quantitatively through meta-analysis. Reasons for excluding the remaining articles are detailed in the flow diagram. Figure 1.

Characteristics of included studies

The seven RCTs were published between 2015 and 2023. All the patients were diagnosed with TMJ osteoarthritis following established criteria, either by RDC/TMD (Group IIIb)[36-38] or the more recent DC/TMD (Axis I, Group IIIb).[39,40] In only one case, although the patients were diagnosed with unilateral TMJ osteoarthritis, the classification criterion was not specified.[41] Additionally, in one study, although the diagnosis of TMJ osteoarthritis was made according to DC/TMD, the patients were included under Axis I, Group Ib.[42] All studies included an intervention group with combined arthrocentesis and a control group with exclusive

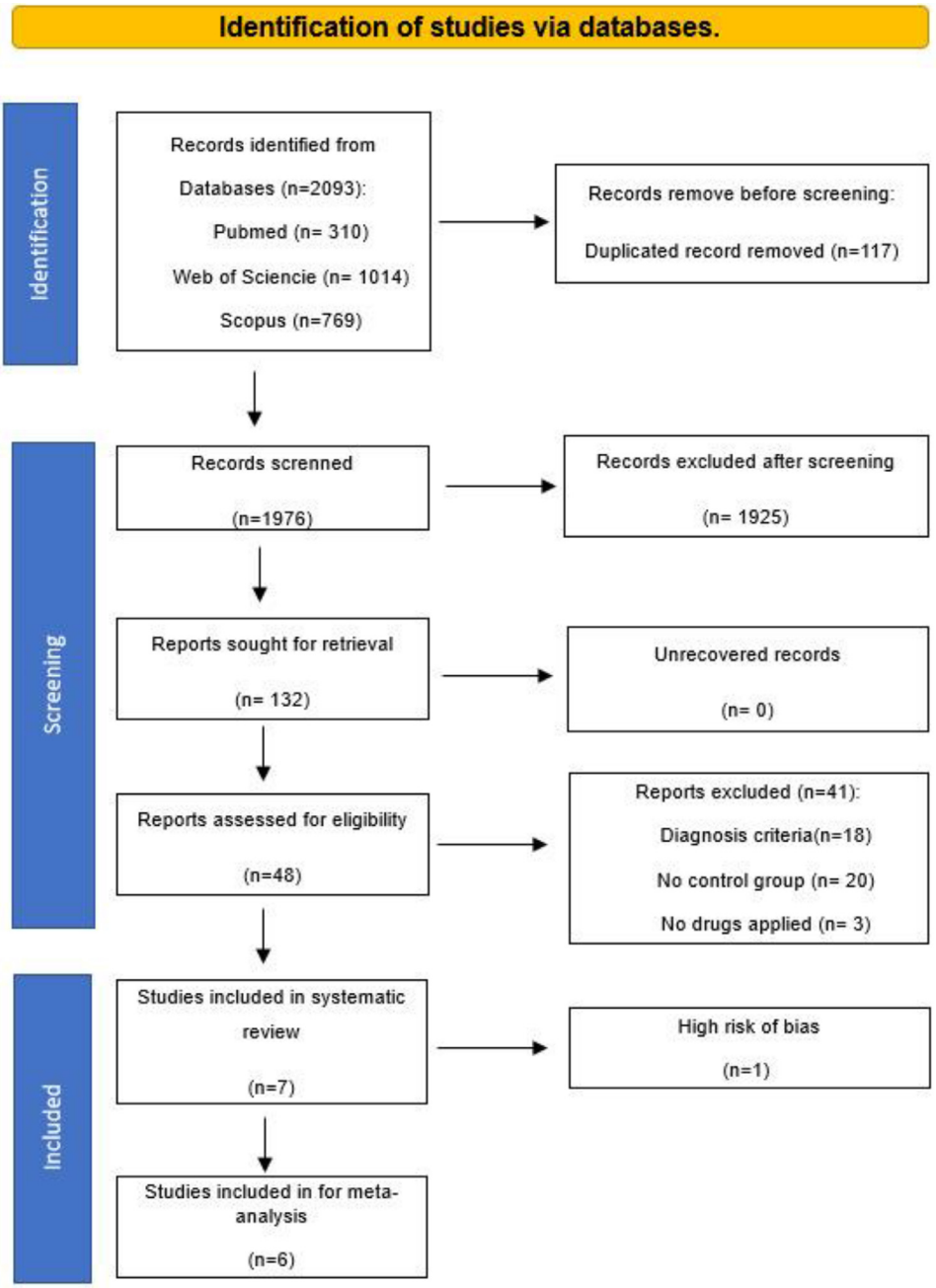

Fig. 1. PRISMA flow chart.

arthrocentesis. One study additionally featured a third group receiving PRP infiltration alone, without prior arthrocentesis.[42] The arthrocentesis technique was performed in all cases using the double-needle technique. For complementary therapy to arthrocentesis in the intervention groups, several elements were utilized:

- PRP was obtained by centrifuging venous blood (6ml) mixed with 3.2% sodium citrate as an anticoagulant at 1000 rpm for 10 minutes.[37,41]
- PRF was obtained by extracting a venous blood sample, storing it in a 10ml non-coated plastic tube, and centrifuging it at 700rpm for 3 minutes.[40]
- Hyaluronic acid was also used with a base composition of hylan[36] or sodium hyaluronate.[38]
- The drugs administered included corticosteroids (methylprednisolone acetate, Depo-Medrol; Pfizer, New York, NY)[39] and NSAIDs (Tenoxicam, Oksamen-L; Mustafa Nevzat İlaç Sanayi, Istanbul, Turkey).[42]

All included RCTs assessed pain and maximum mouth opening, though pain was measured inconsistently across studies. For this meta-analysis, equivalent measures such as pain on palpation[36,40] and pain complaints[37,39] were used, while some studies[38,41,42] did not specify the pain measurement methods. Other variables were analyzed. All information related to each study is available in Table 1.

Risk of bias in included studies

The evaluation of the risk of bias revealed that most studies demonstrated moderate to high (4:2) methodological quality. For more information, see Supplementary Table 2 and Supplementary Figure. 1. The greatest bias identified arises from missing or unclear details about the blinding method, with some RCTs[40,41] providing better descriptions. Additionally, certain authors[36] did not explain the sample size selection process.

Effects of the interventions

The mean age of the subjects ranges from 26.45 ± 4.66 to 51.55 ± 14.5. The female-to-male ratio is 152:27. The results focus on the most common follow-up periods of six and twelve months, excluding other follow-up periods from the meta-analysis due to insufficient comparative data and evidence.

Results from individual studies

Abbadi et al.[41] reported an increase in maximum mouth opening without significant differences between groups (P = .090) and significant pain reduction across all study groups (P < .001), with the greatest benefits observed in the combined arthrocentesis with PRP group in a single session (P = .000)

Cömert Kiliç et al.[37] found a reduction in pain in both groups after twelve months, with a more pronounced effect in the combined arthrocentesis with PRP group followed by a cycle of four monthly PRP injections without prior arthrocentesis (P < .001). However, No significant differences were observed between the groups (P > .05), and the increase in maximum mouth opening was not statistically significant for either group (P > .05).

Işik et al.[40] found that the group treated with combined arthrocentesis and PRF, followed by four weekly PRF cycles, achieved significantly better maximum mouth opening values and pain reduction (P < .001).

Bergstrand et al.[36] observed significant pain reduction within both groups after six months, but no differences between the groups (P > .05). After forty-seven months, no differences in pain reduction were found between the groups (P = .276).

Gurung et al.[38] found pain reduction in both groups without significant differences (P = .007). However, maximum mouth opening increased significantly (P = .004) in the group treated with combined arthrocentesis and hyaluronic acid therapy over a five-week cycle compared to the group treated with arthrocentesis alone over a five-week cycle.

Cömert Kiliç[39] found significant pain reduction in both groups after twelve months, with a slightly greater reduction in the combined therapy group (P < .01; P < .05), though differences were not statistically significant (P > .05). Maximum mouth opening increased in the group treated with arthrocentesis with corticosteroids whereas it decreased in the control group, with no significant differences between the groups (P > .05).

Baraymoglu et al.[42] found no significant differences in maximum mouth opening (P = .174) or pain reduction (P = .085) between the combined arthrocentesis with NSAIDs group and the control group after six months of follow-up.

Results of meta-analysis

Maximum mouth opening in millimeters at six months of follow-up. In the terms studied in this analysis, the studies showed no significant heterogeneity ($\tau 2$ = 1.93, I2 = 29%; Heterogeneity test: Q = 1.41, p-value = .234), indicating that the studies are comparable to each other according to the common effects model.

According to the common effects model, the maximum mouth opening measured at six months was 3.69 (95% CI: 0.86−6.52) units higher in the intervention groups than in the control groups (P = .011). Figure 2.

Maximum mouth opening in millimeters at twelve months of follow-up. The studies showed non-significant heterogeneity (τ^2= 2.1, I^2 = 0 %; Heterogeneity Test: Q = 2.64, p-value = .267), indicating that the studies are comparable among themselves according to the common effects model. According to the common effects model, the maximum mouth opening measured at twelve months was 2.76 (95% CI: 2.44-3.08) units greater in the intervention groups than in the control groups (P < .001) Figure 3.

Pain at six months of follow-up. In the terms studied in this analysis, the studies showed significant heterogeneity ($\tau 2$ = 2.46, I2 = 82%; Heterogeneity test: Q = 11.31, p-value = .003), indicating that the differences between the studies are considerable. In this sense, it is necessary to interpret the model with random effects since it assumes that the true effects can vary between studies and averages these effects considering the heterogeneity among them.

The random effects model determines that the pain measured at six months was 1.02 (95% CI: 2.96-0.91) units lower in the intervention groups than in the

Table 1. General characteristics of included studies

Study, year (country)	*Diagnosis*	*Groups*	*Sample size*	*Mean age (±SD)*	*Gender*	*Volume lavage*	*Sessions*	*Joints*	*Needle-gauge*	*Follow-up*	*Variables*
Bergstrand et al.[36] (Norway)	RDC/TMD Osteoarthritis	Control: Arthrocentesis	17	55 ± 14.5	Male: 6 Female: 11	Ringer's Lactate	1	17	Not contribute	47 months	Maximun mouth opening Pain Lateral motion Contralateral motion Protrusive motion Sounds (no sounds clicking, crepitation, clicking+crepitation)
		Experimental: Arthrocentesis +Hyauloric acid	20	47 ± 15.7	Male: 1 Female: 19	1mL Synvisc (Genzyme Co.) MW: 6000kDa	1	20			
Işık et al.[40] (Turkey)	DC/TMD Axis I, Temporomandibular Joint Osteoarthritis	Control: Arthrocentesis	18	45.72 ± 13.12	Male: 1 Female: 17	200mL Normal saline	1	21	20-gauge needle	48 weeks	Maximun mouth opening Pain at Palpation Chewing Pain Pain jaw movements Lateral motion Protrusive motion
		Experimental: Arthrocentesis +injectable PRF	18	44.67 ± 12.13	Male: 2 Female: 16	1mL PRF	1 Arthrocentesis+ PRF (4 injectable PRF weekly)	22			
Cömert et al.[37] (Turkey)	RDC/TMD (Axis I, group IIIb)	Control: Arthrocentesis	12	35.08 ± 14.84	Male: 1 Female:11	100mL Ringer's Lactate	1	15	20-gauge needle	48 weeks	Maximun mouth opening with/without pain Pain Masticatory efficiency Sounds Cone Bean Computed Tomography findings
		Experimental: Arthrocentesis +PRP	18	32.22 ± 14.33	Male: 2 Female: 16	1mL PRP	1 Arthrocentesis+ PRP (4 PRP monthly)	32			
Cömert Killiç[39] (Turkey)	DC/TMD (Axis I, group IIIb)	Control: Arthrocentesis	12	35.08 ± 14.84	Male:1 Female: 11	100mL Ringer's Lactate	1	15	20-gauge needle	48 weeks	Masticatory efficiency Pain complaints Joint sounds Maximun mouth opening with/without pain Lateral motion Protrusive motion
		Experimental: Arthrocentesis + Methylprednisolone acetate	12	32.58 ± 9.58	Male: 2 Female: 10	1mL Methylprednisolone acetate	1	17			
Bayramoglu et al.[42] (Turkey)	DC/TMD (Axis I, group Ib)	Control: Arthrocentesis	14	43.35 ± 11.10	Male: 2 Female: 12	100mL Ringer's Lactate	1	Not contribute	Not contribute	24 weeks	Maximun mouth opening Pain Sounds
		Experimental: Arthrocentesis +Tenoxicam	16	40.75 ± 12.06	Male: 4 Female: 12	2mL Tenoxicam	1				
Abbadi et al.[41] (Syria)	Unilateral Temporomandibular Joint Osteoarthritis	Control: Arthrocentesis	11	27.09 ± 7.38	Male: 2 Female: 9	50mL Normal saline	1	Right: 4 Left: 7	21-gauge needle	24 weeks	Maximun mouth opening Pain Sounds
		Experimental first: Arthrocentesis +PRP	11	26.45 ± 4.66	Male: 3 Female: 8	5mL Normal saline+ 1mL PRP	1	Right: 5 Left: 6			
		Experimental second: intra-articular PRP	11	28.73 ± 7.73	Male: 4 Female: 7	1mL PRP	1	Right: 8 Left: 3			
Gurung et al.[38] (India)	RDC/TMD (Axis I, Group IIIb)	Control: Arthrocentesis	10	18-60 years old	Male: 6 Female: 4	Ringer's Lactate	5	Not contribute	18-gauge needle	12 weeks	Maximum mouth opening Pain Painful/pain- free lateral protrusive motion Joint sounds Cone Bean Computed Tomography findings Tumor necrosis factor alpha and Interleukin-6 in lavage fluid
		Experimental: Arthrocentesis +sodium hyaluronic acid	10		Male: 8 Female: 2	0.5mL sodium hyaluronic acid (synolife 20mg/ml) MW: not contribute	5				

MW, Molecular Weight; kDa, kilo Dalton.

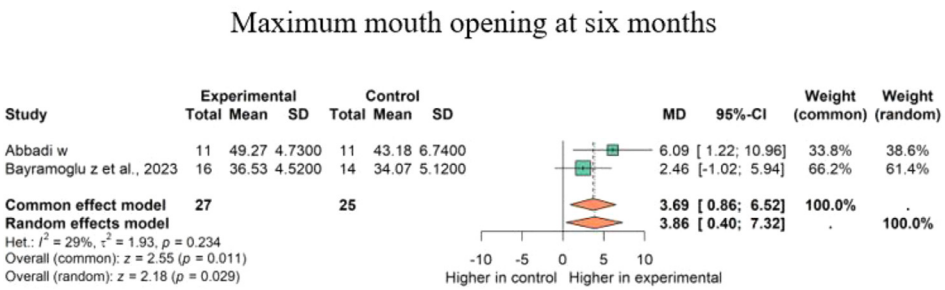

Fig. 2. Maximum mouth opening 6 months.

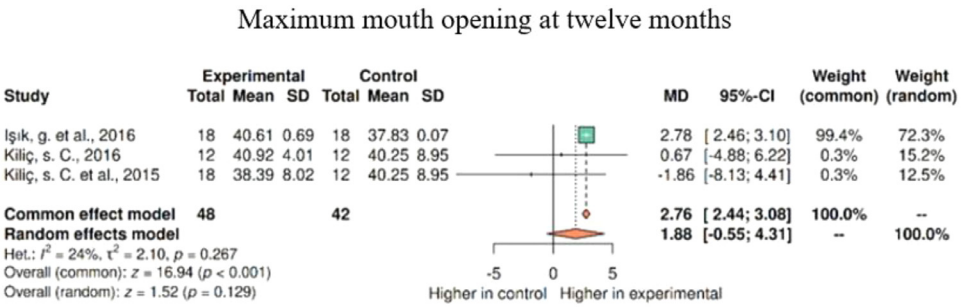

Fig. 3. Maximum mouth opening 12 months.

Fig. 4. Pain 6 months.

control groups, although these differences were not significant (P = .300). Figure 4

Pain at twelve months of follow-up. The studies showed non-significant heterogeneity (τ^2 = 0, I^2 = 8.6 %; Heterogeneity Test: Q = 2.19, p-value = .335), indicating that the studies were comparable among themselves according to the common effects model. According to the common effects model, the pain measured at twelve months was 1.61 [95% CI: 2.07-1.15] units lower in the intervention groups than in the control groups (P < .001). Figure 5.

Certainty of evidence. The analysis of the certainty of evidence, based on the GRADE guidelines, was carried out using the GRADEpro GDT tool (version 2023; Evidence Prime: Hamilton, ON, Canada, 2023). Thus, the evaluation obtained after the meta-analysis for maximum mouth opening and pain, at each follow-up time, was rated with moderate certainty. This rating was mainly determined by the degree of imprecision caused by the small sample sizes used in the studies. The inconsistency in the pain variable at the six months follow-up was addressed using the random-effects model. Consequently, this initial inconsistency did not significantly impact the assessment of the quality of the evidence. The analysis of the quality of evidence is shown in Supplementary Table 3.

DISCUSSION

TMJ osteoarthritis is a degenerative disease that significantly impacts patients' quality of life. Arthrocentesis with Ringer's lactate or saline solution is a safe and effective technique, particularly when other conservative treatments fail.[18] To enhance the effectiveness of this procedure, various drugs and compounds have

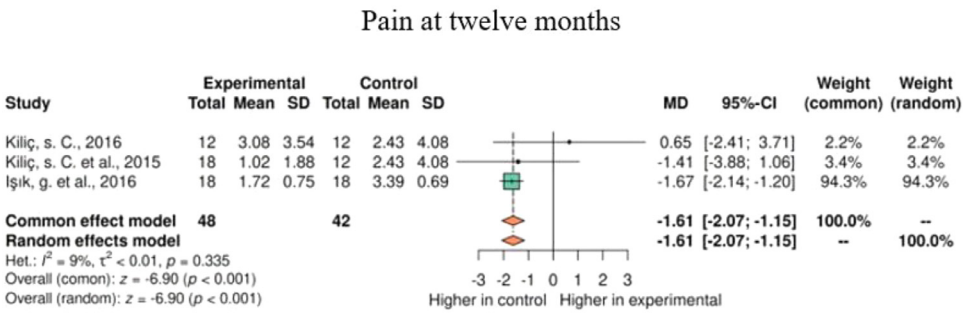

Fig. 5. Pain 12 months.

been proposed.[21-24,26] However, the variability in treatment protocols and the heterogeneity of reported outcomes underscore the need for direct comparisons between arthrocentesis alone and combined arthrocentesis to determine the most effective approach.

This meta-analysis evaluated six RCTs including 179 patients with TMJ osteoarthritis, comparing combined arthrocentesis therapies to isolated arthrocentesis. After six months, combined arthrocentesis with PRP or NSAIDs significantly improved maximum mouth opening (P = .011).[41,42] However, no significant differences were observed in pain reduction (P = .030) when comparing combined techniques using different compounds (NSAIDs, PRP, or hyaluronic acid) to isolated arthrocentesis.[36,41,42] While combined therapies enhance mouth opening, they do not offer superior pain relief.

At the twelve-month follow-up, combined arthrocentesis (PRP, PRF, or corticosteroids) showed statistically significant improvements (P < .001) in both maximum mouth opening and pain reduction compared to the control group.[37,39,40] These findings suggest that, in the long term, combined arthrocentesis provides superior outcomes for both variables.

The literature contains numerous studies exploring arthrocentesis in TMJ disorders, including intra-articular injections with various compounds. A systematic review and network meta-analysis[28] comparing intra-articular injections (hyaluronic acid, corticosteroids, PRP) with or without arthrocentesis versus a placebo (Ringer's lactate) in TMJ osteoarthritis patients found no significant differences in pain relief or mouth opening at three, six, or twelve months. However, another systematic review and meta-analysis assessing the effectiveness of arthrocentesis, arthrocentesis with PRP, and arthrocentesis with PRF in patients with TMJ internal disorders[43] reported a significant and progressive increase in maximum mouth opening with combined therapies compared to the control group. Similarly, pain reduction was significantly greater in the PRP and PRF groups, with PRF showing earlier improvements, making it the most effective option.

A systematic review by Guarda-Nardini et al.[30] comparing various drugs for TMJ osteoarthritis treatment concluded that single-session arthrocentesis with PRP was more effective than isolated single-session arthrocentesis. Additionally, hyaluronic acid outperformed placebo but was less effective than PRP and PRF. PRP showed slightly better pain management than PRF after six months, whereas PRF led to greater improvements in mouth opening after three and six months. Despite these differences, PRF was considered the most effective treatment. Xu et al.[17] conducted a systematic review and meta-analysis comparing hyaluronic acid, PRP, and PRF with or without arthrocentesis versus isolated arthrocentesis in TMD patients. Their findings confirmed that while hyaluronic acid was more effective than placebo at three and six months, it was consistently less effective than PRP and PRF, with PRF yielding the best results across all follow-up periods.

Among the RCTs included in this meta-analysis, single-session arthrocentesis with hyaluronic acid showed no significant improvements after six months.[36] However, when administered in five-week cycles, it significantly improved pain and mouth opening at three months compared to the control group.[38] Guarda-Nardini et al.[30] also concluded that multi-session arthrocentesis was more effective than single-session arthrocentesis, particularly when combined with hyaluronic acid. Similarly, Manfredini et al.[44] compared six different arthrocentesis protocols, including two combined arthrocentesis protocols with low and high molecular weight hyaluronic acid over five sessions in TMJ osteoarthritis patients. They found that five-session combined therapy with low molecular weight hyaluronic acid provided the best pain relief and mandibular mobility improvements, although the differences between groups were not statistically significant. Guarda-Nardini et al.[45] obtained similar results when comparing single-session and five-session combined arthrocentesis with different molecular weights of hyaluronic acid, reporting significant improvements in masticatory efficiency and pain reduction but no

significant differences in mouth opening or perceived treatment efficacy.

Goiato et al.[27] conducted a systematic review comparing the effectiveness of hyaluronic acid, NSAIDs, and corticosteroids in TMD patients, primarily those with TMJ osteoarthritis. They concluded that hyaluronic acid, whether injected alone or combined with arthrocentesis, was effective in pain management and mandibular function, similar to NSAIDs and corticosteroids. However, Davoudi et al.[46] comparing arthrocentesis with corticosteroids to other conservative and minimally invasive treatments, found that corticosteroids did not provide superior benefits over other arthrocentesis adjuncts. Gencer ZK et al.[47] assessed the efficacy of hyaluronic acid, the NSAID Tenoxicam, and the corticosteroid Betamethasone versus a saline solution control in TMD patients. Their results showed that after six weeks, the hyaluronic acid group had the best pain reduction ($P < .05$), followed by the Betamethasone group. In contrast, Tenoxicam provided only short-term relief, losing effectiveness after the first week.

This systematic review and meta-analysis uniquely evaluate the effectiveness of combined arthrocentesis across different drug groups versus isolated arthrocentesis, addressing an underexplored topic. However, several limitations should be noted. First, only six clinical trials met the inclusion criteria. Second, the small sample sizes of the included studies introduced a degree of imprecision. Third, the meta-analysis focused on the most commonly reported variables, potentially omitting other relevant data. Fourth, follow-up periods were selected based on the most frequently reported time points, leading to the exclusion of other timeframes and potentially missing short-term effects of some combined therapies. Fifth, no studies meeting the inclusion criteria directly compared different NSAIDs and corticosteroids. Lastly, while random-effects models were used to address inconsistencies, the results related to pain reduction at six months remain less reliable.

Future RCTs should include larger sample sizes and follow-up periods that comprehensively evaluate short-, medium-, and long-term outcomes. Additionally, protocols similar to the successful five-week arthrocentesis cycles with hyaluronic acid should be explored for PRP and PRF therapies, as suggested by Cömert Kiliç et al.[37] and Işik et al.[40]

In conclusion, combined arthrocentesis improves maximum mouth opening in the medium and long term compared to isolated arthrocentesis, while pain reduction becomes significant only after twelve months. Further studies with standardized protocols and larger sample sizes are needed to ensure more consistent findings.

ACKNOWLEDGMENTS

The authors would like to acknowledge University of Las Palmas de Gran Canaria for their support.

PRESENTATION

This systematic review and meta-analysis were presented as a poster at the first international meeting of the societies of the Spanish Society of Craniomandibular and Orofacial Pain and the Portuguese Society of Orofacial Pain on May 17, 2024, in Seville, Spain.

FUNDING

This research did not receive any specific grant from funding agencies in the public, commercial, or not-for-profit sectors.

DECLARATION OF COMPETING INTEREST

The authors declared no potential conflicts of interest with respect to the research, authorship, and/or publication of this article.

CREDIT AUTHORSHIP CONTRIBUTION STATEMENT

Marilia Betancor Pérez: Conceptualization, Funding acquisition, Investigation, Methodology, Resources, Writing – original draft. **Juan Francisco Loro Ferrer:** Methodology, Supervision, Writing – review & editing. **Fátima Martín Hernán:** Supervision, Writing – review & editing. **Rocío Trinidad Velázquez Cayón:** Data curation, Formal analysis, Methodology, Writing – review & editing.

SUPPLEMENTARY MATERIALS

Supplementary material associated with this article can be found in the online version at doi:10.1016/j.oooo.2025.06.003.

REFERENCES

1. Paulino MR, Moreira VG, Lemos GA, Silva PLP da, Bonan PRF, Batista AUD. Prevalence of signs and symptoms of temporomandibular disorders in college preparatory students: associations with emotional factors, parafunctional habits, and impact on quality of life. *Cien Saude Colet*. 2018;23(1):173-186. https://doi.org/10.1590/1413-81232018231.18952015.
2. Alzahrani A, Yadav S, Gandhi V, Lurie AG, Tadinada A. Incidental findings of temporomandibular joint osteoarthritis and its variability based on age and sex. *Imaging Sci Dent*. 2020;50(3):245-253. https://doi.org/10.5624/isd.2020.50.3.245.
3. Dos Anjos Pontual ML, Freire J, Barbosa J, Frazão M, dos Anjos Pontual A, Fonseca da Silveira MM. Evaluation of bone changes in the temporomandibular joint using cone beam CT. *Dentomaxillofac Radiol*. 2012;41(1):24-29. https://doi.org/10.1259/dmfr/17815139.
4. Murphy MK, MacBarb RF, Wong ME, Athanasiou KA. Temporomandibular disorders: a review of etiology, clinical management, and tissue engineering strategies. *Int J Oral Maxillofac Implants*. 2013;28(6):e393-e414. https://doi.org/10.11607/jomi.te20.

5. Ahmad M, Schiffman EL. Temporomandibular joint disorders and orofacial pain. *Dent Clin North Am*. 2016;60(1):105-124. https://doi.org/10.1016/j.cden.2015.08.004.
6. International classification of orofacial pain, 1st edition (ICOP). *Cephalalgia*. 2020;40(2):129-221. https://doi.org/10.1177/0333102419893823.
7. Hunter A, Kalathingal S. Diagnostic imaging for temporomandibular disorders and orofacial pain. *Dent Clin North Am*. 2013;57(3):405-418. https://doi.org/10.1016/j.cden.2013.04.008.
8. Delpachitra SN, Dimitroulis G. Osteoarthritis of the temporomandibular joint: a review of aetiology and pathogenesis. *Br J Oral Maxillofac Surg*. 2022;60(4):387-396. https://doi.org/10.1016/j.bjoms.2021.06.017.
9. Look JO, Schiffman EL, Truelove EL, Ahmad M. Reliability and validity of axis I of the research diagnostic criteria for temporomandibular disorders (RDC/TMD) with proposed revisions: Reliability and validity of axis i of the research diagnostic criteria. *J Oral Rehabil*. 2010;37(10):744-759. https://doi.org/10.1111/j.1365-2842.2010.02121.x.
10. Schiffman E, Ohrbach R, Truelove E, et al. Diagnostic Criteria for Temporomandibular Disorders (DC/TMD) for clinical and research applications: Recommendations of the international RDC/TMD consortium network* and orofacial pain special interest group. *J Oral Facial Pain Headache*. 2014;28(1):6-27. https://doi.org/10.11607/jop.1151.
11. Manfredini D, Guarda-Nardini L, Winocur E, Piccotti F, Ahlberg J, Lobbezoo F. Research diagnostic criteria for temporomandibular disorders: a systematic review of axis I epidemiologic findings. Oral Surg Oral Med Oral Pathol Oral Radiol Endod. 2011;112(4):453-462. doi:10.1016/j.tripleo.2011.04.021
12. Boutault F, Cavallier Z, Lauwers F, Prevost A. Temporomandibular joint arthroplasty for osteoarthrosis: A series of 24 patients that received a uni- or bilateral inter-positional silicone sheet. *J Stomatol Oral Maxillofac Surg*. 2018;119(3):199-203. https://doi.org/10.1016/j.jormas.2018.02.004.
13. Tvrdy P, Heinz P, Zapletalova J, Pink R, Michl P. Effect of combination therapy of arthrocentesis and occlusal splint on nonreducing temporomandibular joint disk displacement. *Biomed Pap Med Fac Univ Palacky Olomouc Czech Repub*. 2015;159(4):677-680. https://doi.org/10.5507/bp.2014.044.
14. Nitzan DW, Dolwick MF, Martinez GA. Temporomandibular joint arthrocentesis: a simplified treatment for severe, limited mouth opening. *J Oral Maxillofac Surg*. 1991;49(11):1163-1167. https://doi.org/10.1016/0278-2391(91)90409-f.
15. Kumar S, Kiran K, Yadav A. Temporomandibular joint arthrocentesis: a prospective study and audit of 500 joints of central India. *J Int Soc Prev Community Dent*. 2018;8(2):124. https://doi.org/10.4103/jispcd.jispcd_361_17.
16. Dhiman NK, Jaiswara C, Hirani MS, Chauhan N, Mahajan AD, Krishnan A. Efficacy of arthrocentesis with intra-articular injection of hyaluronic acid and corticosteroid in the treatment of internal derangement of temporomandibular joint. *Natl J Maxillofac Surg*. 2023;14(1):93-100. https://doi.org/10.4103/njms.njms_8_22.
17. Xu J, Ren H, Zhao S, et al. Comparative effectiveness of hyaluronic acid, platelet-rich plasma, and platelet-rich fibrin in treating temporomandibular disorders: a systematic review and network meta-analysis. *Head Face Med*. 2023;19(1):39. https://doi.org/10.1186/s13005-023-00369-y.
18. Torres D, Zaror C, Iturriaga V, Tobias A. Intra-articular corticosteroids for treatment of temporomandibular joint internal disorders: protocol for systematic review and network meta-analysis. *BMJ Open*. 2020;10(9):e034327. https://doi.org/10.1136/bmjopen-2019-034327.
19. Sequeira J, Rao BHS, Kedia PR. Efficacy of sodium hyaluronate for temporomandibular joint disorder by single-puncture arthrocentesis. *J Maxillofac Oral Surg*. 2019;18(1):88-92. https://doi.org/10.1007/s12663-018-1093-4.
20. Parlawar AN, Mundada BP. Enhancing pain relief in temporomandibular joint arthrocentesis: platelet-rich plasma and hyaluronic acid synergy. Cureus.
21. Egierska D, Perszke M, Mazur M. Duś-Ilnicka I. Platelet-rich plasma and platelet-rich fibrin in oral surgery: a narrative review. *Dent Med Probl*. 2023;60(1):177-186. https://doi.org/10.17219/dmp/147298.
22. Honvo G, Reginster JY, Rannou F, et al. Safety of intra-articular hyaluronic acid injections in osteoarthritis: outcomes of a systematic review and meta-analysis. *Drugs Aging*. 2019;36(Suppl 1):101-127. https://doi.org/10.1007/s40266-019-00657-w.
23. Liu Y, Wu JS, Tang YL, Tang YJ, Fei W, Liang XH. Multiple treatment meta-analysis of intra-articular injection for temporomandibular osteoarthritis. *J Oral Maxillofac Surg*. 2020;78(3):373.e1-373.e18. https://doi.org/10.1016/j.joms.2019.10.016.
24. Ferreira N, Masterson D, Lopes de Lima R, et al. Efficacy of viscosupplementation with hyaluronic acid in temporomandibular disorders: a systematic review. *J Craniomaxillofac Surg*. 2018;46(11):1943-1952. https://doi.org/10.1016/j.jcms.2018.08.007.
25. Derwich M, Mitus-Kenig M, Pawlowska E. Mechanisms of action and efficacy of hyaluronic acid, corticosteroids and platelet-rich plasma in the treatment of temporomandibular joint osteoarthritis: a systematic review. *Int J Mol Sci*. 2021;22(14):7405. https://doi.org/10.3390/ijms22147405.
26. Ribeiro H, Rodrigues I, Napoleão L, et al. Non-steroidal anti-inflammatory drugs (NSAIDs), pain and aging: adjusting prescription to patient features. *Biomed Pharmacother*. 2022;150(112958):112958. https://doi.org/10.1016/j.biopha.2022.112958.
27. Goiato MC, da Silva EV, de Medeiros RA, Túrcio KH, Dos Santos DM. Are intra-articular injections of hyaluronic acid effective for the treatment of temporomandibular disorders? A systematic review. *Int J Oral Maxillofac Surg*. 2016;45(12):1531-1537. https://doi.org/10.1016/j.ijom.2016.06.004.
28. Xie Y, Zhao K, Ye G, Yao X, Yu M, Ouyang H. Effectiveness of intra-articular injections of sodium hyaluronate, corticosteroids, platelet-rich plasma on temporomandibular joint osteoarthritis: a systematic review and network meta-analysis of randomized controlled trials. *J Evid Based Dent Pract*. 2022;22(3):101720. https://doi.org/10.1016/j.jebdp.2022.101720.
29. Li J, Chen H. Intra-articular injection of platelet-rich plasma vs hyaluronic acid as an adjunct to TMJ arthrocentesis: A systematic review and meta-analysis. *J Stomatol Oral Maxillofac Surg*. 2024;125(2):101676. https://doi.org/10.1016/j.jormas.2023.101676.
30. Guarda-Nardini L, De Almeida AM, Manfredini D. Arthrocentesis of the temporomandibular joint: systematic review and clinical implications of research findings. *J Oral Facial Pain Headache*. 2021;35(1):17-29. https://doi.org/10.11607/ofph.2606.
31. Siewert-Gutowska M, Pokrowiecki R, Kamiński A, Zawadzki P, Stopa Z. State of the art in temporomandibular joint arthrocentesis-A systematic review. *J Clin Med*. 2023;12(13). https://doi.org/10.3390/jcm12134439.
32. Page MJ, McKenzie JE, Bossuyt PM, et al. Declaración PRISMA 2020: una guía actualizada para la publicación de revisiones sistemáticas. *Rev Esp Cardiol*. 2021;74(9):790-799. https://doi.org/10.1016/j.recesp.2021.06.016.
33. Munn Z, Tufanaru C, Aromataris E. JBI's systematic reviews: data extraction and synthesis. *Am J Nurs*. 2014;114(7):49-54. https://doi.org/10.1097/01.NAJ.0000451683.66447.89.
34. Guyatt GH, Oxman AD, Vist GE, et al. GRADE: an emerging consensus on rating quality of evidence and strength of recommendations. *BMJ*. 2008;336(7650):924-926. https://doi.org/10.1136/bmj.39489.470347.AD.

35. Balduzzi S, Rücker G, Schwarzer G. How to perform a meta-analysis with R: a practical tutorial. *Evid Based Ment Health*. 2019;22(4):153-160. https://doi.org/10.1136/ebmental-2019-300117.
36. Bergstrand S, Ingstad HK, Møystad A, Bjørnland T. Long-term effectiveness of arthrocentesis with and without hyaluronic acid injection for treatment of temporomandibular joint osteoarthritis. *J Oral Sci*. 2019;61(1):82-88. https://doi.org/10.2334/josnusd.17-0423.
37. Cömert Kiliç S, Güngörmüş S, Sümbüllü M. Is arthrocentesis plus platelet-rich plasma superior to arthrocentesis alone in the treatment of temporomandibular joint osteoarthritis? A randomized clinical trial. *J Oral Maxillofac Surg*. 2015;73(8):1473-1483. https://doi.org/10.1016/j.joms.2015.02.026.
38. Gurung T, Singh RK, Mohammad S, Pal US, Mahdi AA, Kumar M. Efficacy of arthrocentesis versus arthrocentesis with sodium hyaluronic acid in temporomandibular joint osteoarthritis: A comparison. *Natl J Maxillofac Surg*. 2017;8(1):41-49. https://doi.org/10.4103/njms.NJMS_84_16.
39. Cömert Kiliç S. Does injection of corticosteroid after arthrocentesis improve outcomes of temporomandibular joint osteoarthritis? A randomized clinical trial. *J Oral Maxillofac Surg*. 2016;74(11):2151-2158. https://doi.org/10.1016/j.joms.2016.05.027.
40. Işık G, Kenç S, Özveri Koyuncu B, Günbay S, Günbay T. Injectable platelet-rich fibrin as treatment for temporomandibular joint osteoarthritis: a randomized controlled clinical trial. *J Craniomaxillofac Surg*. 2022;50(7):576-582. https://doi.org/10.1016/j.jcms.2022.06.006.
41. Abbadi W, Z Kara Beit, Arthrocentesis Al-Khanati NM. Injectable Platelet-Rich Plasma and Combination of Both Protocols of Temporomandibular Joint Disorders Management: A Single-Blinded Randomized Clinical Trial. *Cureus*. 2022;14(11):e31396. https://doi.org/10.7759/cureus.31396.
42. Bayramoglu Z, Yavuz GY, Keskinruzgar A, Koparal M, Kaya GS. Does intra-articular injection of tenoxicam after arthrocentesis heal outcomes of temporomandibular joint osteoarthritis? A randomized clinical trial. *BMC Oral Health*. 2023;23(1):131. https://doi.org/10.1186/s12903-023-02852-z.
43. Nagori SA, Gopalakrishnan V, Rangarajan H, Kulkarni V, Roychoudhury A. Does intra-articular injection of platelet-rich plasma/platelet-rich fibrin improve outcomes after temporomandibular joint arthrocentesis? A systematic review and meta-analysis. *Br J Oral Maxillofac Surg*. 2024;62(8):676-684. https://doi.org/10.1016/j.bjoms.2024.06.007.
44. Manfredini D, Rancitelli D, Ferronato G, Guarda-Nardini L. Arthrocentesis with or without additional drugs in temporomandibular joint inflammatory-degenerative disease: comparison of six treatment protocols*. *J Oral Rehabil*. 2012;39(4):245-251. https://doi.org/10.1111/j.1365-2842.2011.02265.x.
45. Guarda-Nardini L, Rossi A, Arboretti R, Bonnini S, Stellini E, Manfredini D. Single- or multiple-session viscosupplementation protocols for temporomandibular joint degenerative disorders: a randomized clinical trial. *J Oral Rehabil*. 2015;42(7):521-528. https://doi.org/10.1111/joor.12282.
46. Davoudi A, Khaki H, Mohammadi I, Daneshmand M, Tamizifar A, Bigdelou M, Ansaripoor F. Is arthrocentesis of temporomandibular joint with corticosteroids beneficial? A systematic review. *Med Oral Patol Oral Cir Bucal*. 2018;23(3):e367-e375. https://doi.org/10.4317/medoral.21925.
47. Gencer ZK, Özkiriş M, Okur A, Korkmaz M, Saydam L. A comparative study on the impact of intra-articular injections of hyaluronic acid, tenoxicam and betametazon on the relief of temporomandibular joint disorder complaints. *J Craniomaxillofac Surg*. 2014;42(7):1117-1121. https://doi.org/10.1016/j.jcms.2014.01.041.